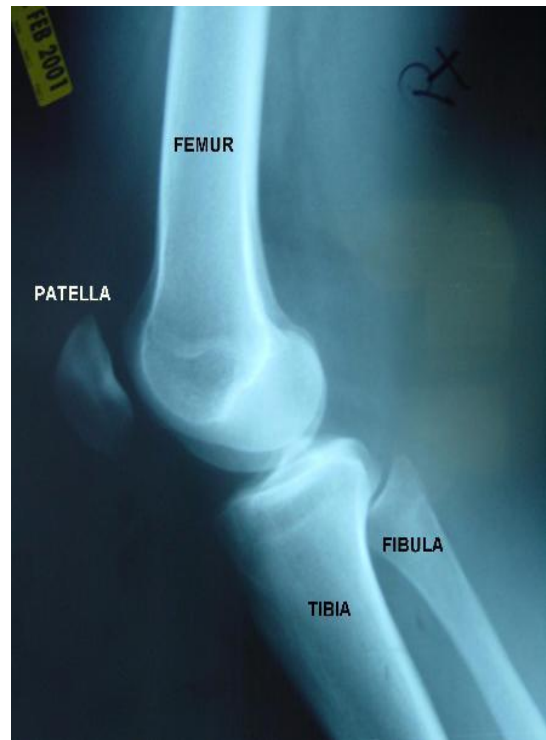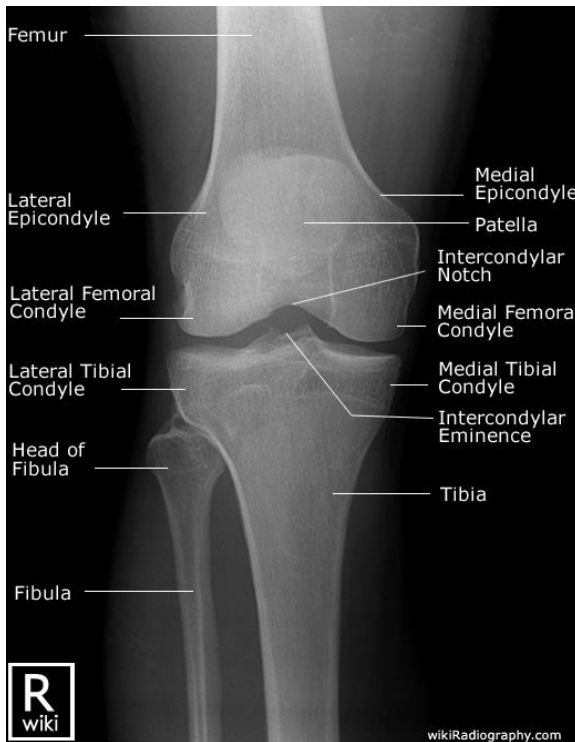


## Unit VII – Problem 5 – Radiology: Osteoarthritis



- Most commonly affected joint by osteoarthritis is the knee joint.
- Below are normal radiographs of the knee joint:



- Specific radiological changes of the knee joint in osteoarthritis:
  - **Joint space narrowing.**
  - **Osteophytes.**
  - **Subchondral sclerosis.**
  - **Subchondral cysts.**
  - **Loose bodies.**

