

Unit VII – Problem 8 – Histology: Skin & Appendages



- The integumentary system consists of the skin and appendages which include:

- Sweat glands.
- Sebaceous glands.
- Hair (with arrector pili muscle).
- Nails.

- General functions of the integumentary system are:

- Protection from mechanical injury.
- Physical barrier against the entry of pathogens.
- Chemical prevention against the entry of pathogens.
- Sensation and thermoregulation.
- Metabolic functions.

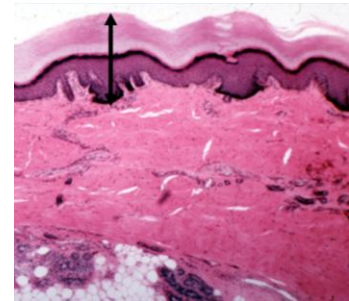
- Layers of the skin:

- **Epidermis (developing from ectoderm).** It is the superficial, avascular layer which is consisting of 4-5 layers of epithelial cells resting on a basement membrane.
- **Dermis (developing from mesoderm).** It is the deep, vascular layer which is consisting of fibrous connective tissue (+ contains the appendages). This layer is of 2 types:
 - ✓ Papillary (containing loose connective tissue).
 - ✓ Reticular (containing dense connective tissue).

- **Hypodermis.**

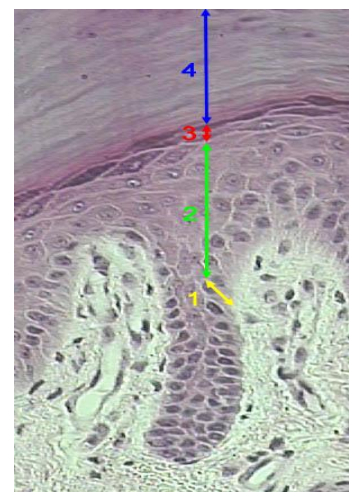
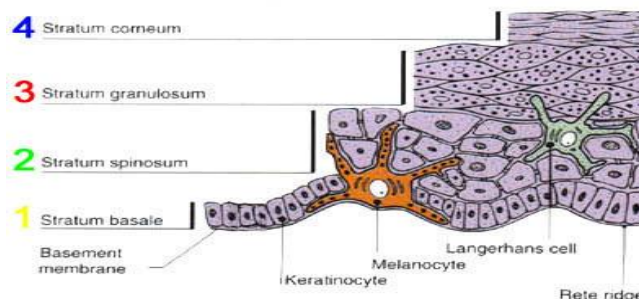
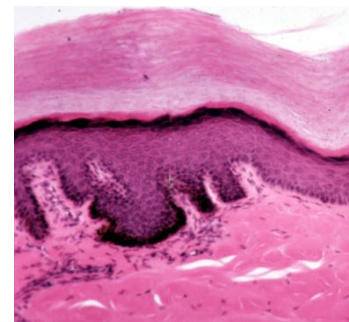
- Epidermis (see the image: indicated by the black arrow):

- All characteristics which were mentioned above.
- **Epidermal cell types:**
 - ✓ Keratinocytes (structure).
 - ✓ Melanocytes (pigment: color of the skin).
 - ✓ Merkel cells (sensation).
 - ✓ Langerhan's cells (antigen presenting cells for the immune system of the skin).



- Types of skin:

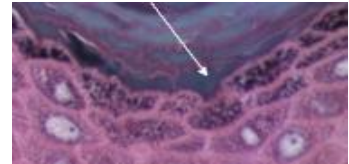
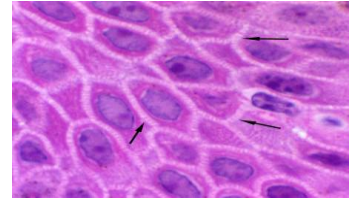
- **Thick skin (see the image):**
 - ✓ Found on soles of feet, palms of hands and corresponding parts of fingers and toes.
 - ✓ Contains 5 epidermal strata (sheets/layers):
 - ❖ Stratum basale.
 - ❖ Stratum spinosum.
 - ❖ Stratum granulosum.
 - ❖ Stratum lucidum.
 - ❖ Stratum corneum.
- **Thin skin:**
 - ✓ Found everywhere else on the body.
 - ✓ Contains 4 epidermal strata (lacks stratum lucidum): thinner of those of the thick skin.





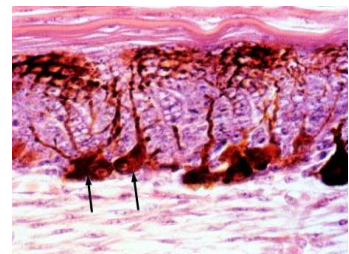
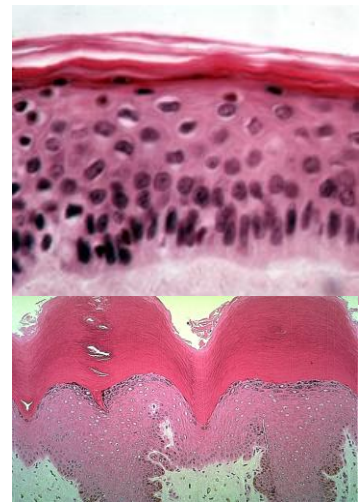
- Strata of the skin:

- **Stratum basale:** it is the deepest epidermal layer which is firmly attached to the dermis. It is composed of a single row of cuboidal keratinocytes (melanocytes and Merkel cells are interspersed). Cells in this layer are highly mitotic.
- **Stratum spinosum (see the image):** it is the 2nd deepest layer which is consisting of 8-10 layers of cells (cells of lower layers might be mitotic). These cells begin to flatten and make precursors of keratin (they are connected by desmosomes).
- **Stratum granulosum:** 3-5 cell layers thick. Cells continue to flatten and their nuclei and organelles disintegrate. There will be accumulation of granules in these cells which contain a precursor of keratin and waterproofing agent.
- **Stratum lucidum (see the image):** 3-5 layers of flat, dead keratinocytes. Appears clear when viewed by light microscope (because it lacks nuclei and organelles).
- **Stratum corneum:** it is the outermost stratum which is consisting of 20-30 layers of squamous, keratinized, dead cells. The process by which cells in the stratum basale divide and then advance upward becoming more keratinized and less alive as they go is known as (cornification).



- Cells of the epidermis:

- **Keratinocytes (see the image):**
 - ✓ Most numerous (found in all layers of the epidermis).
 - ✓ Function: production of keratin (providing strength and protection).
 - ✓ Connected to each other by desmosomes (causing the skin to flake off in sheets rather than as individual cells).
 - ✓ When keratinocytes move farther from the deepest layer, they make the keratin that eventually dominates their cell contents (becoming scale-like bags of keratin).
 - ✓ Keratohyaline granules: they contain intermediate filament associated proteins which help in keratin aggregation.
 - ✓ Lamellar bodies: responsible for formation of intercellular epidermal water barrier.
- **Melanocytes (see the image: indicated b arrows)**
 - ✓ Spider-shaped epithelial cells synthesizing the protein pigment (melanin). Melanin is packaged into membrane-bound granules called melanosomes. Granules are transferred to the sunny-side of the nucleus of keratinocytes in the two deepest layers of the epidermis.
 - ✓ Melanin granules protect the DNA within the nucleus from being damaged by the UV light from the sun.
 - ✓ They are found in the deepest layer of the epidermis (stratum basale) migrating to it from the neural crest.
 - ✓ Biochemistry: tyrosine is converted to DOPA by the enzyme tyrosinase. DOPA will be converted to melanin (albinos are unable to synthesize tyrosinase).

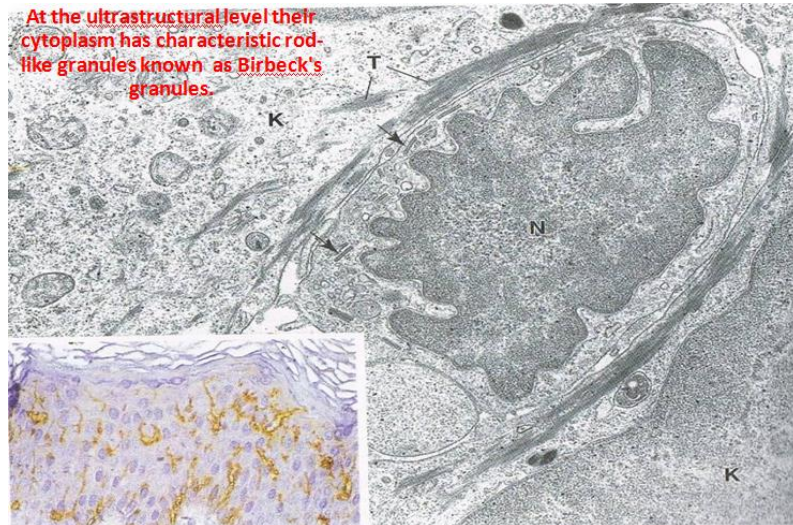




- ✓ Differences in skin color result from melanin content (not number of melanocytes!). these differences can also be due to:
 - ❖ Endocrine (ACTH).
 - ❖ Genetics.
 - ❖ Gender.
 - ❖ Pregnancy.
 - ❖ Environmental (exposure to UV light).

- **Langerhan's cells (see the image below):**

- ✓ Star-shaped cells found in the stratum spinosum.
- ✓ They are derived from the bone marrow.
- ✓ Blood-borne cells which are capable of binding and processing.
- ✓ They function as antigen presenting cells for the immune system of the skin.



- **Merkel cells:**

- ✓ Derived from neural crest and found in stratum basale in areas of high tactile sensitivity and at the base of hair follicles.
- ✓ Commonly associated with free nerve endings.
- ✓ Function: sensory mechanoreceptors and produce local neuroendocrine secretions.

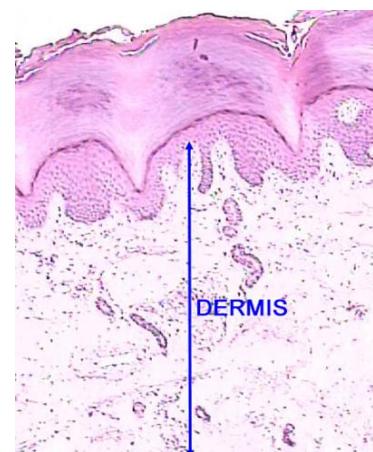
- **Skin color:**

- **It is due to 3 pigments (Note that only melanin is made in the skin):**

- ✓ Melanin: ranges in color from yellow to reddish brown to black. Freckles and moles are local accumulations of melanin.
- ✓ Carotene: yellow to orange pigment found in carrots. When large amounts are eaten it can be deposited in stratum corneum of thick skin.
- ✓ Hemoglobin (Hb): it is a pigmented protein that transports oxygen within the blood. In Caucasians, the fair skin allows the crimson color of oxygenated blood to make the skin have a somewhat pinkish hue.

- **Dermis (see the figure):**

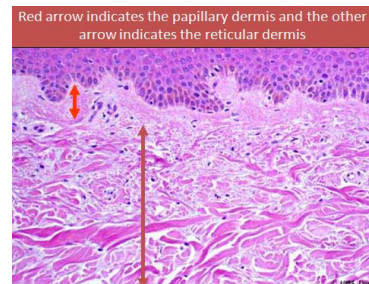- Strong, flexible, fibrous connective tissue.
- **2 divisions:**
 - ✓ Papillary (see the image in next page):
 - ❖ It is the upper 1/5 of the dermis and consists of loose connective tissue.
 - ❖ Provides an arena for immune cells to fight invaders.





- ❖ Dermal papillae form a strong connection with epidermis.
- ❖ Vascular and contains multiple sensory receptors.
- ✓ Reticular (see the image):

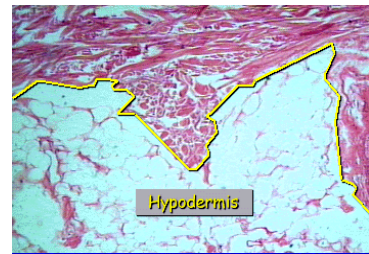
- ❖ It is the lower 4/5 of the dermis and consists of irregular dense connective tissue (collagen provides strength and elastin provide stretching ability).
- ❖ Majority of appendages are contained within the dermis.



- Note that with aging, the collagen fibers thicken and cross-link and the elastic fibers lose much of their elasticity, causing increased wrinkling of the skin.

- Hypodermis (see the image):

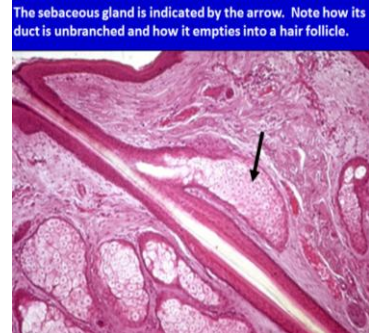- It is a subcutaneous layer composed mainly of adipose tissue (different distribution between sexes) which insulate and provide energy.
- The border between dermis and hypodermis is indistinct.



- Appendages of the skin:

- **Sebaceous glands (see the image: indicated by the black arrow):**

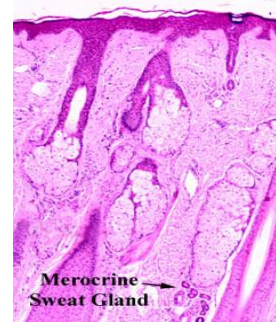
- ✓ They are acinar glands (with several acini opening into a short duct which usually ends at the upper portion of a hair follicle).
- ✓ They open at the epidermis directly in: glans penis, lips and clitoris.
- ✓ Sebum: it is the secretion of sebaceous glands
- ✓ Sebaceous glands are holocrine glands (in which the product of secretion is released with remnants of dead cells).



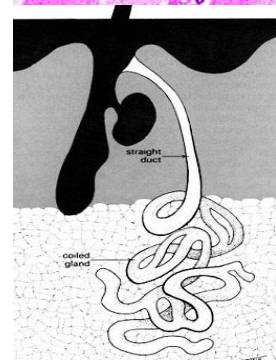
- **Sweat glands:**

- ✓ Distributed over the entire body except the nipples and portions of the external genitalia.
- ✓ There are 2 types of sweat glands:

- ❖ *Merocrine sweat glands (see the image):* more numerous; prominent on palms, soles and forehead; simple, coiled, tubular glands; duct empties at a funnel-shaped pore at the skin surface; major function is thermoregulation; sweat contains salts (NaCl), vitamin C, antibodies and small amounts of nitrogenous wastes; pH of the sweat is 4-6 (creating acid mantle which is bacteriostatic).



- ❖ *Apocrine sweat glands (see the image):* found in axillary, pubic and anal regions of the body; larger than merocrine sweat glands; become active at puberty; play no role in thermoregulation; ducts empty into hair follicles; sweat is thicker and contains more lipids and proteins (when degraded by epidermal bacteria → foul odor is produced).



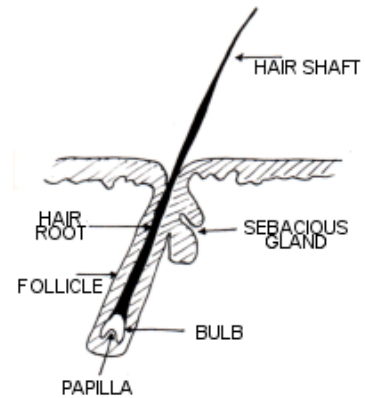


- **Ceruminous glands:**

- ✓ Modified apocrine glands in the inner lining of the external ear canal.
- ✓ They secrete sticky waxy substance called the cerumen (earwax). It combines with sebum and dead epidermal cells to form a bitter (مَرِّ-لاذِع) compound that offers a barrier to entry of the ear.

- **Hair and hair follicles:**

- ✓ Hair is a flexible strand made of highly keratinized dead cells.
- ✓ Keratin of hair and nails is (hard keratin) while that of the epidermis is (soft keratin).
- ✓ Hair is made by the living hair follicle.
- ✓ Hair consists of (see the image):
 - ❖ A shaft which protrudes from the skin.
 - ❖ A root which is within the skin.
 - ❖ At the base, the root gets wider forming the hair bulb.



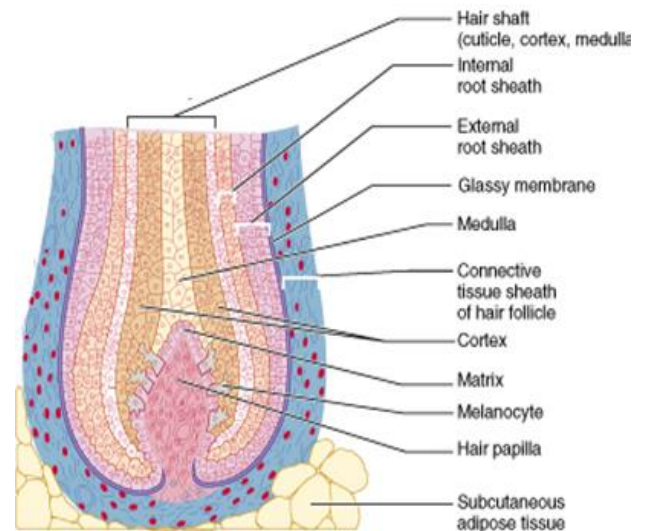
- ✓ The hair consists of 3 concentric regions:

- ❖ *Medulla*: innermost region; consisting of large cells and air spaces.
- ❖ *Cortex*: surrounds the medulla; consisting of flattened keratinized cells.
- ❖ *Cuticle*: outer layer; consisting of flat keratinized cells that overlap like shingles with their free edges pointing upward.

- ✓ The hair follicle contains:

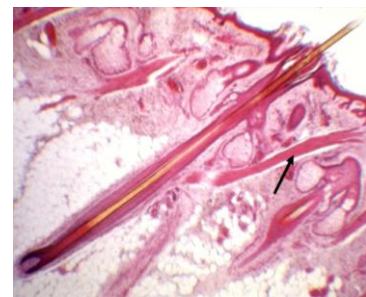- ❖ Outer connective tissue sheath.
- ❖ Inner epithelial root sheath (internal root sheath & external root sheath).

Hair matrix: a single layer of mitotic cells at the base of hair follicle (they are derived from stratum basale). All the cells of the hair are derived from the hair matrix. Just beneath the hair matrix is an obvious dermal papilla called the hair papilla (it contains the blood vessels that nourish the matrix and the cells of the hair follicle).



- ✓ Hair root plexus: a network of sensory nerve endings wrapped around the bulb of the hair follicle.

- ✓ Arrector pili muscle (see the image: indicated by the black arrow): a bundle of smooth muscle attached to the hair. In times of fright or cold, these muscles contract and cause the hair to stand on end and produces (goose bumps).



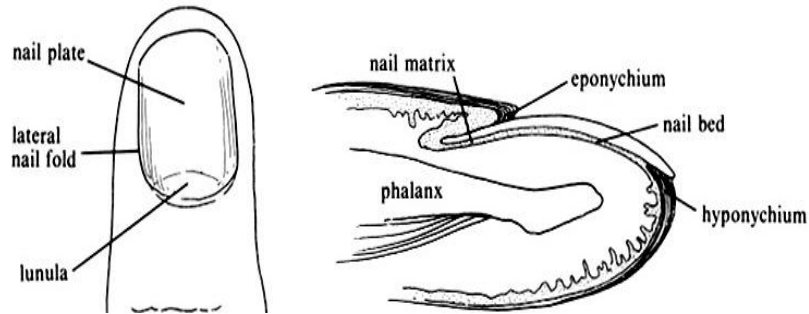
- ✓ Color of hair: black/brown → eumelanin, red → pheomelanin, blonde → intermediate levels of eumelanin and low levels of pheomelanin.

- ✓ Texture of hair: straight → rounded hair shaft, curled → flat hair shaft.



- **Nails:**

- ✓ They are plates of keratinized epithelial cells on the dorsal surface of each distal phalanx of hands and toes (protective covering).
- ✓ Nail root: it is the proximal nail part hidden in the nail groove.
- ✓ Stratum corneum of skin covering nail root forms the eponychium (cuticle).



- ✓ Nails consist of: stratified squamous epithelial cells overlying the nail bed with the lunula as the most actively growing region of the nail root.
- ✓ As new cells are produced, older ones are pushed outward and become keratinized.
- ✓ Functions of nails:
 - ❖ Useful in medical diagnosis: flat or concave in iron deficiency; clubbed in long-term hypoxia.
 - ❖ Tools for digging, grooming and manipulation.

- **Innervation of the skin:**

- **Autonomic sympathetic efferents (unmyelinated):**

- ✓ Adrenergic: vasomotor/pilomotor
- ✓ Cholinergic: secretomotor (eccrine sweat).

- **Somatic sensory afferent:**

- ✓ **Types:**

- ❖ Free nerve endings (located in dermis and epidermis and can extend up to stratum granulosum). They respond to high/low temperatures, pain and itching but also function as tactile receptors (مختص بحاسة اللمس).
- ❖ Capsulated nerve endings.

- ✓ **Functions:**

- ❖ Mechanoreceptors.
- ❖ Thermoreceptors.
- ❖ Nociceptors.

- **Tactile (Meissner's) corpuscles**: tactile mechanoreceptors found in dermal papilla, especially in thick skin, lips, eyelids, genitalia and nipples. They convey light touch.

- **Lamellated (Pacini) corpuscles**: mechanoreceptors common in the dermis of thick skin, and are found in deep in the reticular dermis or hypodermis. They detect pressure and vibration applied on skin surface.

